



# The desperate plea of women with the nutcracker syndrome\*

J. L. Villavicencio

Distinguished Professor of Surgery, Department of Surgery, Uniformed Services University School of Medicine, Bethesda, MD, USA

## Keywords

Meso-aortic renal compression, nutcracker syndrome, pelvic congestion, renal vein obstruction

## Summary

**Objective:** To increase awareness on the severe impact of the nutcracker syndrome in women with undiagnosed disease. **Patients and methods:** We reviewed the medical literature and analyzed six representative series with 73 patients with nutcracker syndrome. Women with left flank pain, dyspareunia, dysuria, dysmenorrhea, micro- or macrohaematuria and pelvic congestion symptoms, should be carefully investigated for evidence of meso-aortic left renal vein compression. A good number of our colleagues do not believe in the existence of the nutcracker syndrome and send these patients in a long pilgrimage in search of someone who can help them to get relief to their pain. New and improved imaging techniques can assist in the diagnosis but retrograde reno-gonadal phlebography and renocaval gradient are the most reliable diagnostic tools. **Results:** Among an assortment of treatment techniques, renal vein transposition and endovenous stenting were the two most commonly used procedures. There are no long term studies on renal vein stenting in children and young adults. Its use in these cases should be carefully considered. The nutcracker syndrome may present with pelvic congestion symptoms and its diagnosis missed. The patient's age, severity of symptoms and haemodynamic renal studies should guide the treatment. **Conclusion:** An increased awareness of the existence of the nutcracker

syndrome may prevent many unfortunate undiagnosed women from spending many months and often years of suffering.

## Schlüsselwörter

Meso-aortale Nierenvenenkompression, Nussknacker-Syndrom, Beckenvenensyndrom, Nierenvenenobstruktion

## Zusammenfassung

**Hintergrund:** Die Kompression der linken Nierenvene im Übergang zwischen Aorta und der oberen Mesenterialarterie (Nussknacker-Phänomen) kann Symptome einer Nierenvenenobstruktion bzw. Hypertonie oder einen schweren venösen Rückstau in der Gonadenevene oder beides verursachen. Die Symptome wie Schmerzen im Lumbalbereich, Dyspareunie, Dysmenorrhö, Hämaturie und ein Beckenvenensyndrom führen Patientinnen zu verschiedenen Fachärzten, die mit dem Nussknacker-Syndrom oft nicht vertraut sind. Die Patientinnen werden depressiv, fühlen sich gestresst und verzweifelt. Wir führten eine umfassende Überprüfung der gegenwärtigen Fortschritte bei der Diagnose und der Behandlung der Patientinnen mit diesem Syndrom durch und aktualisierten die Ergebnisse unserer kürzlich veröffentlichten Erfahrungen. **Materialien und Methoden:** Es wurde eine Recherche der aktuellen medizinischen Literatur durchgeführt und die Ergebnisse einer repräsentativen Untersuchungsreihe an 73 Patientinnen mit Nussknacker-Syndrom tabellarisch dargestellt. Die Tabelle fasst unsere neuesten Erfahrungen bezüglich der operativen und endovaskulären Therapie von 17 Patientinnen mit Nussknacker-

Syndrom zusammen, die in unseren Krankenhäusern untersucht wurden. Die Verdachtsdiagnose aufgrund der klinischen Untersuchung wird durch Bestimmung des renokavalen Gradienten anhand einer retrograden Phlebographie der Nieren- und Gonadenevene (ein Gradient  $>3$  mmHg ist diagnostisch beweisend) oder durch die duplexsonographische Bestimmung der höchsten Strömungsgeschwindigkeit in der Nierenvene bestätigt. Obwohl dreidimensionale Mehrschicht-CT-Angiographie und Magnetresonanztomographie inzwischen häufiger eingesetzt werden, war unserer Erfahrung nach die retrograde Phlebographie der Nierenvene am besten geeignet. **Therapie:** Hauptsächlich zwei Verfahren wurden zur Behandlung schwerer Fälle des Nussknacker-Syndroms angewendet: operative Interventionen und Ballonangioplastie in Kombination mit endovaskulären Stents. Zu den häufigsten Operationsmethoden gehören: Transposition der Nierenvene, gonadokavaler Bypass, Nephropexie, splenorenaler Bypass, Nephrektomie und Transposition der Mesenterialarterie. Leichte Symptome können konservativ behandelt werden. In den meisten Fällen betrug die Nachbeobachtungsphase 12 bis 80 Monate. **Ergebnisse:** Die Auswertung der Ergebnisse der repräsentativen Untersuchungsreihe in der Tabelle zeigt: Bei Patientinnen mit leichten Symptomen ist eine konservative Behandlung gerechtfertigt ( $32/73 = 43,8\%$ ). Bei schweren Fällen erfolgten verschiedene Eingriffe: endovaskuläre Stents ( $8/73 = 11\%$ ), externe Stents ( $2/73 = 2,7\%$ ), Transposition der linken Nierenvene ( $27/73 = 37\%$ ), gonadokavaler Bypass ( $3/73 = 4\%$ ); bei einer Patientin wurde erfolgreich

## Correspondence to:

J. Leonel Villavicencio MD FACS  
Distinguished Professor of Surgery, Department of Surgery, Uniformed Services University School of Medicine, Bethesda MD  
Senior Consultant and Staff, Department of Surgery and Vascular Surgery, Walter Reed Army Medical Center, Washington DC  
E-mail: jvillavicencio@usuhs.edu

## Der verzweifelte Appell der Frauen mit Nussknacker-Syndrom

Phlebologie 2010; 39: 104–111  
Received: February 17, 2010

\* Vortrag zur Verleihung der Ratschow-Gedächtnismedaille durch das Curatorium Angiologiae Internationalis im Rahmen des UIP-Kongresses 2009 in Monaco



ein splenorealer Bypass durchgeführt, allerdings war die Nachbeobachtungsphase relativ kurz. Das Nussknacker-Syndrom kann zu einem Beckenvenensyndrom führen, bei einigen Patientinnen mit Nussknacker-Syndrom wurde irrtümlich eine Embolisation der Gonadenvene durchgeführt, ohne die hämodynamische Obstruktion der Nierenvene zu korrigieren. Diese Methode ist indiziert, wenn ein hämodynamischer Nachweis für einen schweren Rückstau in der Gonadenvene vorliegt und der Venendurchmesser weniger als 12 mm beträgt. Größere Gonadenvenen sollten endoskopisch entfernt werden (Risiko einer Spiralembolisation in großen Venen). Langzeitergebnisse zu endovaskulären Stents scheinen größere Aussagekraft zu haben (bis zu 10 Jahren in manchen Untersuchungsreihen). Die Transposition der Nierenvene ist ein bewährtes Verfahren mit hervorragenden Langzeitergebnissen, aber bis dato wurde der Eingriff, wie auch in unseren Fällen, offen durchgeführt. Über laparoskopische Verfahren wurde ebenfalls berichtet und diese bieten eine gute Alternative zu offenen Eingriffen. **Schlussfolgerungen:** 1.) Patientinnen mit Nussknacker-Syndrom sollten je nach Lebensalter, Schwere der Symptome und hämodynamischen Befund behandelt werden. 2.) Junge Menschen und Kinder sollten mit einer dauerhaften Methode behandelt werden (z. B. Nierenvenentransposition), da Kinder wachsen und Stents nicht mitwachsen. Bisher liegen keine Informationen vor, wie lange Stents bei Kindern wirksam sind. Dies kann sich ändern, da Stents immer besser werden und immer mehr Erfahrungen vorliegen. 3.) Bei Patientinnen mit Nussknacker-Syndrom und schwerem Rückstau in der Gonadenvene sollte die Obstruktion korrigiert und der Rückstau erneut untersucht werden. Falls erforderlich, sollte einige Wochen nach dem Ersteingriff eine Spiralembolisation folgen. 4.) Bei leichten Symptomen sind konservative Behandlung und engmaschige Verlaufsbeobachtung ratsam.

I selected this historic photograph for two reasons (► Fig. 1). The first is that during the IV European American Symposium on Venous Diseases that I chaired in Bethesda in April 1987, a group of prominent European colleagues interested in venous dis-



**Fig. 1** IV European American Symposium on Venous Diseases. Bethesda, Maryland April 1987: Here, the former Leo Widmer, a recognized figure of European Phlebology, placed the Swiss "Thinking cap" on the heads of Drs Norman Rich, John Bergan and Leonel Villavicencio. His reasons? You might guess!

eases strongly advised us to create an American Venous society that at the time was non existent. Our small group began at that time with the task of creating the society that became the American Venous Forum that is now a reality and a prestigious academic organization. The second is that during that meeting I met a young German physician whose papers attracted my attention. That young man is now your president: Professor Eberhard Rabe.

### Nutcracker syndrome

For this important occasion, I chose the subject of the nutcracker syndrome because during the last decade, we have studied in our clinics an increasing number of desperate women with undiagnosed chronic pelvic pain. These women go from doctor to doctor in search of someone who can help them. Typically, women suffering from chronic pelvic pain are young, with stressful jobs, sexually active, often depressed, suffering from anxiety and dyspareunia that leads to frigidity. The constant flank and pelvic dull ache starts to dominate their life and interferes with daily activities. They often have gone through several specialists who offer them different solutions without success. These women are desperate and almost suicidal (2).

The nutcracker syndrome forms part of the so called pelvic venous syndromes. These syndromes constitute an obscure and bizarre chapter of the venous pathology. Compre-



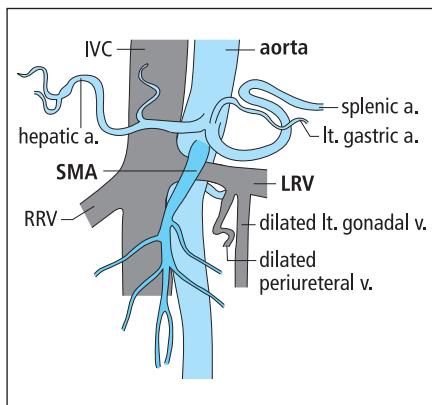
### Max Ratschow

When I received the unexpected letter from Professor **Eberhard Rabe** notifying me that I had been selected to receive the Ratschow Memorial Medal and to deliver the Ratschow Memorial Lecture during the XVI World Congress of the Union International of Phlebology in Monaco, I was deeply honored, surprised, and intrigued. I was surprised to read the impressive list of previous distinguished honorees and to find that my name would join that select group. I was grateful to the Curatorium Angiologiae Internationalis who considered me to receive this honor. I must confess that I was intrigued and unaware of the history and origins of the award. The Ratschow Medal!

Since I firmly believe that any named lecture must recognize those who inspired it, I began the search for information about Professor Max Ratschow and the origins of the award. This is what I learned:

Max Ratschow was born in Rostock in 1904 and died 59 years later. During his relatively short life span, he worked intensively in physiology and pathology and was heavily involved in the care of the wounded soldiers during II world war. He established a clinic for diseases of the vascular system, coined the term *arterial occlusive disease* and is considered the father of angiology in Germany. Ratschow was a leading personality in angiology and phlebology. He was the founder of the Deutschen Arbeitsgemeinschaft für Phlebologie that later became Deutsche Gesellschaft für Phlebologie. He published more than 200 papers and classified the different localizations of arterial occlusions. Ironically and sadly he died suddenly of coronary occlusive disease in 1963.

In his memory, his disciple **Norbert Klüken** established the Max Ratschow Memorial Medal that until now, is the award given annually by the Curatorium Angiologiae Internationalis and Deutsche Gesellschaft für Phlebologie to individuals recognized for their outstanding and meaningful contributions in clinical and research work in the field of angiology and phlebology (1).

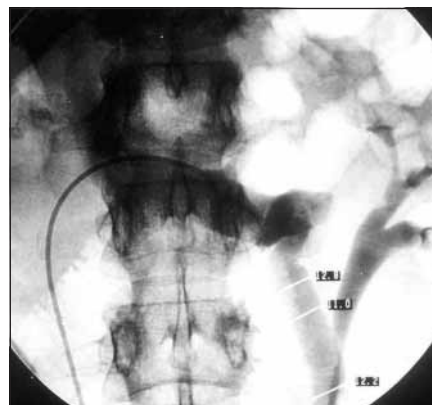


**Fig. 2** Anatomy of the nutcracker syndrome: The left renal vein crosses between the aorta and the superior mesenteric artery. The largest tributary of the renal vein is the ovarian or gonadal vein that may reach large diameter in multiparous women. Compression of the vein results in dilatation of all its tributaries.

sion of the left renal vein as it crosses between the aorta and the superior mesenteric artery (SMA) was first observed in 1950 by El Sadr and Mina in a patient with varicocele (3). Chait described the aorta and the SMA as two arms of a nutcracker that can compress the left renal vein (4). However, the name of *nutcracker phenomeen* was coined by de Schepper (5). Compression of the vein produces severe renal congestion, dilatation of the renal vein and peri-renal and peri-ureteral varicosities. In multiparous women, obstacle to renal venous outflow results in retrograde gonadal vein flow, severe pelvic congestion and left flank pain with pelvic and vulvar varices. The result is the so called nutcracker syndrome with left flank pain and accompanying haematuria that may on occasions be severe.

### Dangerous crossings

The human being is an amazing machine. Those of us who must study anatomy and physiology to become physicians, realize during the very first year of our studies, the marvelous complexity of the human body architecture. Miles of arteries, veins and nerves supported by bones and muscles are controlled and regulated by a remarkable computer system represented by our brain and a pump that does not cease to work for many decades. It is only natural that in a



**Fig. 3** The gonadal vein which normally is 3–4 mm in diameter, may reach large diameter and become incompetent after one or more pregnancies. As observed in this patient, the gonadal vein diameter was over 12mm. It is clear that large retrograde pelvic reflux is often the result of the large gonadal dilatation

machine of this intricacy, the many miles of veins, arteries and nerves, have to cross each other in order to function properly. In certain ways, this network resembles the busy crossroads of highways of a large metropolitan center. However, in spite of all its wonderful architecture, sometimes nature may be less than perfect.

Crossing of veins, arteries and nerves through tight spaces such as the thoracic outlet, the left renal vein between the aorta and superior mesenteric artery, and the vascular crossings in the closed pelvic compartment, may produce clinical symptoms that often require treatment.

A series of so-called dangerous crossings between arteries and veins has been identified. A few of the most frequently described are:

### The thoracic outlet

The neurovascular bundle formed by the subclavian vessels and brachial plexus nerves may be pinched between the first rib, the clavicle and the ligaments and muscles of the neck and shoulder producing venous, arterial or neurologic symptoms.

### The meso-aortic compression of the left renal vein

In this syndrome (nutcracker phenomenon), the left renal vein is compressed in the angle between the superior mesenteric artery and the abdominal aorta as it crosses to drain into the inferior vena cava (► Fig. 2).

The compression of the left common iliac vein by the right common iliac artery also called May-Thurner or Cockett syndrome may produce severe obstructive left venous symptoms with edema and sometimes extensive deep venous thrombosis (6–9).

## Pelvic venous syndromes

### Symptoms

Patients complain of chronic, dull, diffuse pelvic and left flank pain radiating to the buttock, dysmenorrhea, dysuria, dyspareunia that may be so severe as to produce anxiety and frigidity. Painful vulvar and extremity varices are often present, haematuria may be microscopic or on occasions severe, orthostatic proteinuria, varicocele and haematuria. The latter are symptoms that often lead male patients to seek consultation with an urologist.

### Etiology

Controversies regarding the etiology of these syndromes are as lively today as they were when first described. However, new advances in the non invasive and invasive techniques have allowed us to recognize four haemodynamic sources of the symptoms:

- gonadal venous insufficiency,
- insufficiency of the internal iliac vein and its tributaries,
- combination of gonadal and internal iliac venous insufficiency known as pelvic dumping syndrome
- meso-aortic compression of the left renal vein.

### Gonadal insufficiency

The gonadal vein which normally has 3–4 mm internal diameter (ID) and 2–3 com-



petent valves, after one or more pregnancies may reach large diameter and its valves become incompetent. As observed in some patients, the gonadal vein ID may reach 12–15 mm or more. It is clear that large retrograde pelvic reflux is often the result of the large gonadal dilatation (► Fig. 3).

### Isolated reflux of the internal iliac vein and its tributaries

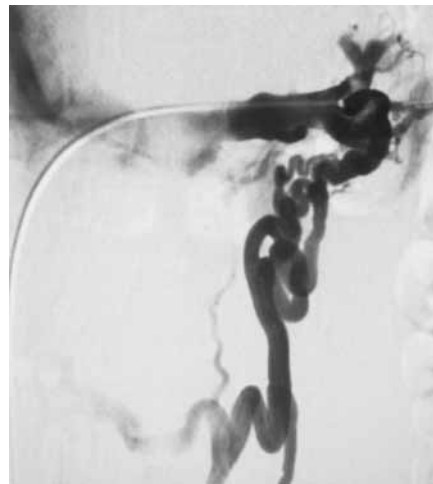It is responsible for large venous lakes, pelvic congestion symptoms and for postoperative recurrence of varicose veins of the lower extremities connected with intrapelvic veins. The internal iliac vein collects blood from the parietal and visceral territories: the parietal are the superior and inferior gluteals, sacral, iliolumbar, obturator and hemorrhoids. The visceral are the vesical, vaginal, uterine, internal pudendal, and rectal plexuses (10, 11). The internal iliac vein through its tributaries connect with extrapelvic veins that may become varicose.

### Combined gonadal and internal iliac venous insufficiency

The distribution of varicosities in the vulva and medial and posterior aspects of the thigh are characteristic of gonado-iliac massive reflux or pelvic dumping syndrome (12). To treat these varices one must first eliminate the gonadal reflux using coil embolization or in cases of very large gonadal veins (> 12 mm ID), laparoscopic or extraperitoneal excision of the vein is recommended. To prevent postoperative recurrences, this procedure must be preceded by coil embolization of the tributaries of the internal iliac vein that are source of extrapelvic venous reflux.

### Meso-aortic compression of the left renal vein

Compression of the left renal vein as it crosses between the aorta and the superior mesenteric artery produces severe renal hypertension, renal congestion, dilatation of the renal vein and peri-renal and periureteral varicosities. Obstacle to renal venous outflow results in retrograde gonadal vein flow and severe pelvic congestion with pelvic and vulvar varices (► Fig. 4).



**Fig. 4** The retrograde cine-video-angiography shows clearly the site of meso-aortic compression as well as the tortuosity and dilatation of the gonadal plexus. The diagnosis of nutcracker syndrome must be confirmed by the determination of the reno-caval gradient (reference value 0–1 mmHg).

The result is the so called nutcracker syndrome with left flank pain and accompanying proteinuria and haematuria.

### Haemodynamic effects of the nutcracker syndrome

The kidney has one of the highest venous outflow rates in our economy. The high velocity retrograde flow resulting from the renal vein obstruction produces venous hypertension in the territory of the left renal vein and its tributaries including dilatation

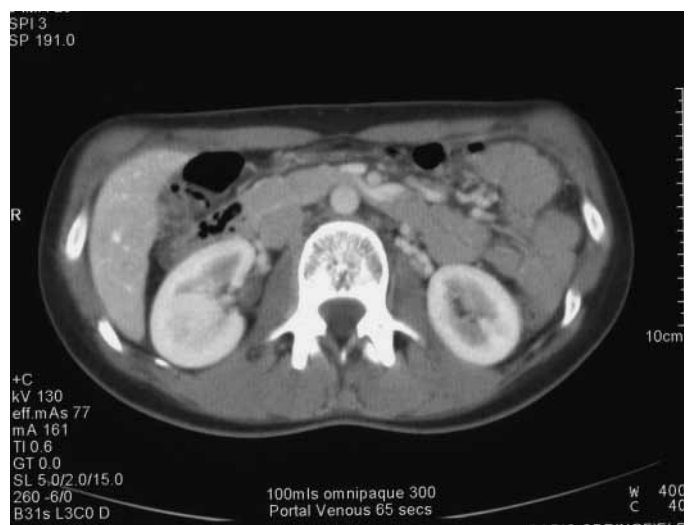and tortuosity of the left gonadal vein, perirenal and peri-ureteral tributaries. Left renal venous hypertension is responsible for the dull flank pain, dysuria, dysmenorrhea and hematuria as well as for the pelvic congestion symptoms often observed in these patients (13–15).

### Diagnosis

Diagnosis of mesoaortic compression of the left renal vein should be suspected clinically by a history of micro or macro hematuria, chronic left flank pain that sometimes radiates to the gluteal area and laboratory analysis showing proteinuria, red blood cells). Gynaecological (endometriosis), urological and gastrointestinal disorders must be ruled out.

It must be confirmed by multi-slice 3D CTA (computed tomography angiography) (16–18), magnetic resonance imaging, colour Doppler ultrasound sonography with determination of peak reno-caval vein velocities (19, 20). The CT scan image of the left renal vein compressed between the aorta and SMA is suggestive but not diagnostic. Anatomic radiological pinching of the renal vein is not equal to hemodynamic obstruction. However, a contrast CT scan and MRA imaging are of great diagnostic value when compression of the left renal vein is accompanied by dilated and varicose peri-renal and peri-ureteral tributaries and clinical symptoms (► Fig. 5).

**Fig. 5** Diagnosis of the nutcracker syndrome: A CT scan is of great value when compression of the left renal vein and dilated peri-renal tributaries are clearly visible. These findings together with the clinical symptoms of flank pain, hematuria, dysuria and dyspareunia may establish the diagnosis.





**Tab.** Representative series of surgical and endovascular techniques in the treatment of nutcracker syndrome

first author (ref)	patients (n)	F-Up mean (months)	treatment	result	haemodynamic studies	observations
				good (%)	gradient mmHg	haematuria, flank pain
Chung BI (51)	1	12	spleno-renal shunt LAP	100	>4	yes, microscopic
Hartung O (45)	5	44	L renal vein stenting	40	4.3	1 stent migration, 2 stents dislodgment, 2 patients o. k.
Wang L (29)	23	42.6	7 LRV TRP 16 conservative	85	>4	6 asymptomatic
Nanette R (26)	23	mean 70	11 LRV TRP 12 conservative.	15/23	2–6	6 had varicocele
Scultetus A, Villavicencio JL (44)	17	18–82	5 LRV TRP 2 ES, 3 GCB, 3 EVS 4 conservative	10/17	2–14	yes; 1 ES thrombosed & recanalized.
Fu WJ (18)	4	N/A	LRV TRP	100	SMA/Ao angle	haematuria

LAP: laparoscopic; LRV: left renal vein ; TRP: transposition; ES: external stent; EVS: endovenous stent; GCB: gonado caval bypass; SMA/Ao: superior mesenteric artery/aorta CT angle determination

Demonstration of a reno-caval gradient either by duplex ultrasound or even better by retrograde selective renal and gonadal phlebography with cine-video-angiography and pull back reno-caval gradient determination may be considered the definitive test since it measures the gradient and visualizes the distorted anatomy of the gonadal vein and perirenal structures. The normal renocaval pullback mean gradient range is from 0 to 1 mmHg as demonstrated by Beinart et al. in a group of 50 apparently healthy individuals (21). Direct varicography has also been used in patients with vulvar and gluteal varices to demonstrate the extrapelvic-intrapelvic connections.

### Differential diagnosis

Gynaecological disorders: endometriosis, pelvic inflammatory disease, polycystic ovaries, urinary and bowel disease must be ruled out by consultation with gynaecology, urology and gastroenterology. As mentioned previously, some female patients suffer anxiety, depression, frigidity as well as social and psychological behavioral disorders secondary to dyspareunia and chronic pelvic and flank pain. A good psy-

chological evaluation is essential in these cases.

### Treatment options

Even though the main objective in reviewing the subject and presenting our experience with the nutcracker syndrome has been our interest in calling the attention of some skeptic colleagues of the medical profession to the unquestionable existence of this syndrome and the disabling symptoms affecting some desperate women attending our clinics, it should be acknowledged that the first cases reported in the medical literature were men presenting with varicocele, haematuria and pain (22). The first reported case of surgical treatment of the nutcracker syndrome in the English literature was performed by Pastershank who divided a *fibrous tunnel* between the aorta and the mesenteric artery in a man with haematuria and left flank pain (23). Several surgical and endovascular techniques have been reported to treat the nutcracker syndrome.

Our own experience in the management of the nutcracker syndrome as well as a representative sample of procedures used in its management are summarized (► Tab.).

Nephropexy has been performed particularly in thin patients with little retroperitoneal and perirenal fat where the kidneys literally hang at the sides of the spine and drop into the renal space. To correct the resultant renal ptosis the kidney needs to be reattached to neighboring structures. In these cases as well as in others with the nutcracker syndrome, the prone position relieves the pain. The explanation is that the weight of the intestinal mass pulls the SMA forward opening the SMA/ aortic angle. In ptotic kidneys, the prone position relieves the problem at least partially by returning the kidneys to near normal position in the abdomen.

Gonado-caval by-pass using 15 mm ID ring-reinforced Gortex grafts has been used successfully as an outflow for the gonadal vein and as an extra outflow channel to alleviate the renal venous hypertension (24).

A segment of PTFE ring-reinforced graft can be wrapped and secured around the renal vein between the aorta and SMA preventing the nutcracker effect (25).

Renal vein reimplantation to a lower site of the inferior vena cava has been reported by several investigators with good results (26–31). This procedure corrects the obstruction to the renal venous outflow and its haemodynamic effects, but in patients



with large gonadal veins (> 12 mmHg ID), does not prevent gonadal reflux. This may result in persistent symptoms of pelvic congestion pain that may require gonadal excision or coil embolization.

We prefer the laparoscopic or retroperitoneal excision of the gonadal vein when its internal diameter exceeds 12 mm since there are reports of symptomatic coil embolization (32).

Other authors do not hesitate in performing gonadal coil embolization preceded by internal iliac vein tributaries embolization. The latter is highly recommended when there are vulvar and lower extremity varices since it eliminates intra-extrapelvic venous reflux and prevents postoperative recurrence of varicose veins of pelvic origin (33–40).

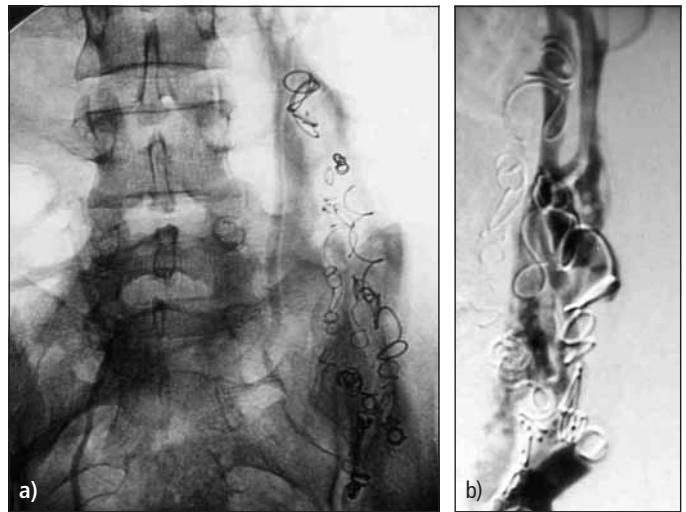
#### Note

Coil embolization of the gonadal veins in our opinion has been over utilized and often used without the necessary haemodynamic documentation to support its potential benefits. Because it is relatively simple to pass a catheter to the gonadal vein in patients with symptoms of pelvic congestion, the procedure of coil embolization has been performed by different types of specialists and the results have not always been uniformly satisfactory. The gonadal vein is rarely a single trunk as we have observed in the anatomy laboratory of our university. Failure to embolize all the trunks may render the procedure less effective (► Fig. 6).

We described the four different potential causes of the symptoms. These must be taken into consideration before performing any therapeutic procedure.

Reports of balloon angioplasty and intraluminal stenting of the renal vein have appeared with increasing frequency in the medical literature. The excellent long term results of Neglen and Raju with endovenous stenting in the ilio-caval system undoubtedly have contributed to stimulate the utilization of this technique in other areas where venous stenosis is the main pathological lesion (41–43). In a previous report on this topic (44) we recommended caution with the use of endovenous stents

**Fig. 6** Embolization of gonadal vein (stainless steel Gianturco coils) to control massive pelvic reflux: The massive retrograde reflux is evident in this retrograde therapeutic gonadal phlebography after coil embolization. Notice the absence of coils in some of the gonadal plexus trunks. This may render the procedure less effective.

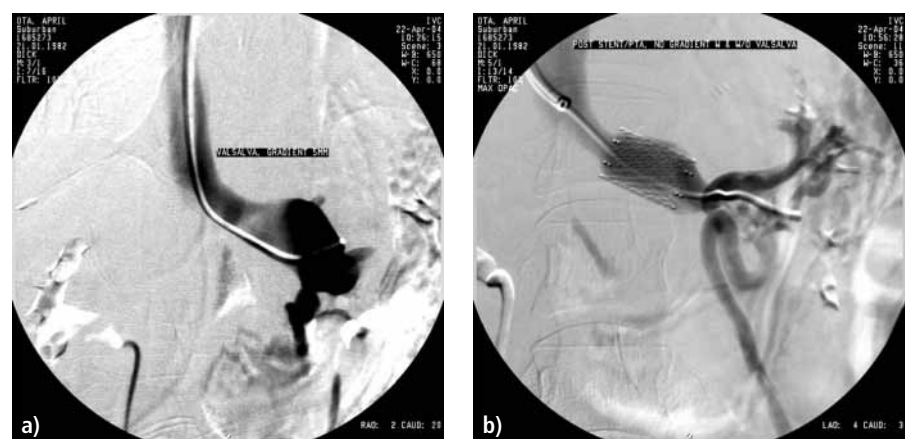

because at the time of our communication, there was limited experience with this technique.

However, at present, endovenous stenting of the renal vein and other venous territories seems to be a safe and effective technique and has become a valuable therapeutic alternative (45–50) (► Fig. 7).

A recently published report from the Cleveland Clinic (51) described the technique of laparoscopic spleno-renal shunt to relieve left renal venous hypertension secondary to the meso-aortic compression in a 29 years old woman. Traditionally, this technique

has been utilized mainly in the treatment of portal hypertension. Chung's report is the first using a spleno-renal shunt to relieve left renal venous hypertension due to the nutcracker syndrome. In Chung's patient the gradient between IVC and the left renal vein was 4 mmHg and 0.5 mmHg in the right renal vein (reference value 0–1 mmHg). However, there is no information in the paper on the pressure on the splenic vein which forms part of the portal venous system. For a shunt to work in the vascular system there must be a gradient. Normal pressure in the portal vein is 5–10 mmHg because the vascular resistance in the hepatic sinusoids is low (52). In Chung's case



**Fig. 7** Nutcracker syndrome

**a)** Brachial access: The use of endovenous stents to treat the meso-aortic compression of the left renal vein has become a good endovascular option. In our first series we used external stenting of the renal vein with ring reinforced Gortex material. The results were good, but the patients have greatly benefited by the new less invasive endovascular approaches gradient in this patient was 4 mm Hg.  
**b)** Renal vein stent: The reno-caval gradient of 4 mmHg was completely abolished after this stent.



there must have been a higher pressure in the renal vein since it is reported that the splenic vein became dilated and the renal vein decreased in size after the bypass.

There are reports of radiological detection of spontaneous splenorenal shunts (53). In the relatively short follow-up the clinical results were good and the patient was asymptomatic at a follow-up visit eight months later. Other more complex invasive surgical procedures that have been reported include mesenteric artery transposition, renal auto-transplantation, and nephrectomy. These are mentioned here for completion even though with the availability of less invasive endovascular /laparoscopic procedures they have become obsolete.

## Conclusion, therapeutic considerations

The choice of treatment must be tailored to

- the severity of the patient's symptoms,
- her/his age, and
- the haemodynamic findings.

It must be determined if there is

- predominant renal outflow obstruction or
- severe gonadal reflux with pelvic venous congestion symptoms or
- if the two haemodynamic conditions coexist.

The appropriate clinical and imaging studies must be performed to establish the diagnosis and investigate the predominant haemodynamic pathology.

- Patients with large, dilated gonadal veins (> 12 mm diameter) and predominant pelvic, vulvar and lower extremity reflux with varicose veins, should have either laparoscopic or extraperitoneal gonadal resection preceded by coil embolization of internal iliac vein tributaries connecting with the extremity varices.
- Patients with gonadal veins <12 mm and symptoms of pelvic venous congestion should be managed by coil embolization.

However, it must be emphasized that a good number of our colleagues, in their

zeal to perform coil embolization of the gonadal vein, base their therapeutic decision mainly on clinical grounds, insufficient radiological assessment and omit a good haemodynamic evaluation. The result is that many patients with nutcracker syndrome have been missed for this reason and the unhappy patient continues her pilgrimage from doctor to doctor in her desperate plea to find relief to her symptoms.

- Patients with predominant symptoms of renal venous hypertension such as left flank pain, haematuria, proteinuria and varicocele in men, and flank pain radiating down to the buttocks, dyspareunia, dysmenorrhea and pelvic congestion in women with or without vulvar, gluteal and lower extremity varices, should have a procedure directed to relieve left renal vein compression and venous outflow obstruction.
- Young patients should be offered renal vein transposition or spleno-renal bypass if the haemodynamic studies are supportive.
- Endovenous renal stenting should be an alternative choice even though in selected cases it may be considered as the preferred option.
- Stenting in children should be avoided since children grow and the stents do not. Whenever possible laparoscopic procedures should be preferred to open surgical procedures. Experience and good criteria should guide our decision.

It is my sincere wish that the contents of this lecture reach to those colleagues who first see these patients because the nature of their specialty (urology, gynecology and gastroenterology) and make them realize that the nutcracker phenomenon really exists and is the cause of misery and despair of many unfortunate patients

## References

1. Rabe E, Pannier-Fisher F, Rabe H (eds). Max Ratschow (1904–1963). In: *Eponyme in der Phlebologie. Biographien und Begriffe*. Köln: Viavital 2002; 113–114.
2. Beard RW. Chronic pelvic pain. *Brit J Obst Gynecol* 1998; 105: 8–10.
3. El Sadr AR, Mina A. Anatomical and surgical aspects of the operative management of varicoceles. *Urol Cutan Rev* 1950; 54: 257–262.

4. Chait A, Matasar KW, Fabian CE, Mellins HZ. Vascular impressions in the ureters. *Am J Roentgenol Radium Nucl Med* 1971; 111: 729–749.
5. De Schepper A. Nutcracker phenomenon van da vena renalis en veneuz pathologie van de linker nier. *J Belge Radiol* 1972; 55: 507–511.
6. Cockett FB, Thomas MI. The iliac compression syndrome. *Br J Surg* 1965; 52: 816–821.
7. Berger A, Jaffe JW, York TN. Iliac compression syndrome treated with stent placement. *J Vasc Surg* 1995; 21: 510–514.
8. Baron HC, Shams J, Wayne M. Iliac vein compression syndrome: a new method of treatment. *Am Surg* 2000; 66: 653–655.
9. Patel NH, Stookey KR, Ketcham DB, Cragg AH. Endovascular management of acute extensive iliofemoral deep venous thrombosis caused by May Thurner syndrome. *J Vasc Interv Radiol* 2000; 11: 1297–1302.
10. Gomez ER, Villavicencio JL, Cofeey JA, Rich NM. Pathogenesis and surgical management of varicose veins of the vulva and upper thigh: the internal iliac venous insufficiency syndrome. In: Veith FJ (ed). *Current Problems in Vascular Surgery*. St Louis: Quality Medical Publishing Co. 1990; 141–142.
11. LePage PA, Villavicencio JL, Gomez ER, Sheridan MN, Rich NM. The valvular anatomy of the iliac venous system and its clinical implications. *J Vasc Surg* 1991; 14: 678–683.
12. Schobinger RA. Iliofemoral dumping syndrome. *V European American Symposium on Venous Diseases*. Vienna, Austria, Nov 1990.
13. Russo D, Minutolo R, Iaccarino V, Andreucci M, Capuano A, Savino FA. Gross hematuria of uncommon origin: the Nutcracker syndrome. *Am J Kid Dis* 1998; 32: 1–4.
14. Hanna HE, Santella RN, Zawada ET, Masterson TE. Nutcracker syndrome: An underdiagnosed cause for hematuria? *SD J Med* 1997; 30: 429–436.
15. Wendel RG, Crawford ED, Hehmann KN. The “nutcracker phenomenon” an unusual cause for renal varicosities with hematuria. *J Urol* 1980; 123: 761–763.
16. Kaneko K, Kiva K, Nishimura K, Shimizu T, Yamashiro Y. Nutcracker phenomenon demonstrated by three-dimensional computed tomography. *Pediatr Nephrol* 2001; 16: 745–747.
17. Cuellar i Calabria H, Quiroga Gomez S, Sebastia Cerqueda C, Bove de la Presa R, Miranda A, Alvarez Castells A. Nutcracker or left renal vein compression phenomenon: multidetector computed tomography findings and clinical significance. *Eur Radiol* 2005; 15: 1745–1751.
18. Fu WJ, Hong BF, Gao JP, Xiao YY, Yang Y, Cai W, Guo G, Wang XX. Nutcracker phenomenon: a new diagnostic method of multislice computed tomography angiography. *Int J Urol* 2006; 13: 870–873.
19. Takebayashi S, Ueki T, Ikeda N, Fujikawa A. Diagnosis of the Nutcracker syndrome with color Doppler sonography: Correlation with flow patterns on retrograde left renal venography. *Am J Roentgen* 1999; 172: 39–43.
20. Seung HK, Seong W C, Hong DK, Jin WCh, Jae HP, Man CH. Nutcracker syndrome: Diagnosis with Doppler US Radiology 1996; 198: 93–97.
21. Beinart C, Sniderman KW, Tamura S, Vaughan ED Jr, Sos TA. Left renal to inferior vena cava pressure relationship in humans. *J Urol* 1982; 127: 1070–1071.



22. Zerhouni EA, Siegelmann SS, Walsh PC, White RI. Elevated pressure in the left renal vein in patients with varicocele: preliminary observations. *J Urol* 1980; 123: 512.
23. Pastershank SP. Left renal vein obstruction by a superior mesenteric artery. *J Canad Ass Rad* 1974; 25: 52–54.
24. Scultetus A, Villavicencio JL, Gillespie DL. The nutcracker syndrome: Its role in the pelvic venous disorders. *J Vasc Surg* 2001; 34: 812–819.
25. Barnes RW, Fleisher HI. III, Redman JE, Smith JW, Harshfield DI, Ferris EJ. Meso-aortic compression of the left renal vein (the so-called nutcracker syndrome): repair by a new stenting procedure. *J Vasc Surg* 1988; 8: 415–421.
26. Nanette RR, Kalra M, Bower TC, Vrtiska TJ, Ricotta JJ. II, Glocviczki P. Left renal vein transposition for nutcracker syndrome. *J Vasc Surg* 2009; 49: 386–394.
27. Stewart BH, Reiman G. Left renal venous hypertension “nutcracker” syndrome. Managed by direct retrocaval reimplantation. *Urology* 1982; 20: 365–369.
28. Kim JY, Joh JH, Choi HY, Do YS, Shin SW, Kim DI. Transposition of the left renal vein in nutcracker syndrome. *Eur J Vasc Endovasc Surg* 2006; 31: 80–82.
29. Wang L, Yang L, Liu Z, Rao J, Liu L, Yang J. Diagnosis and surgical treatment of nutcracker syndrome: a single-center experience. *Urology* 2009; 73: 871–876.
30. Ahmed K, Sampath R, Kahn MS. Current trends in the diagnosis and management of renal nutcracker syndrome: a review. *Eur J Vasc Endovasc Surg* 2006; 31: 410–416.
31. Ishidoya S, Chiba Y, Sakai K, Orikasa S. Nutcracker phenomenon: A case with surgical treatment and its diagnostic criteria. *Acta Urol Jpn* 1994; 40: 135–138.
32. Ratnam LA, Marsh P, Holdstock JM, Harrison CS, Hussain FF, Whiteley MS, Lopez A. Pelvic vein embolization in the management of varicose veins. *Cardiovasc Intervent Radiol* 2008; 31: 1159–1164.
33. Maleux G, Stockx L, Wilms G, Marchal G. Ovarian vein embolization for the treatment of pelvic congestion syndrome: Long term technical and clinical results. *J Vasc Interv Radiol* 2000; 11: 859–864.
34. Venbrux AC, Lambert DL. Embolization of the ovarian veins as a treatment for patients with chronic pelvic pain caused by venous incompetence (pelvic congestion syndrome). *Curr Opin Obstet Gynecol* 1999; 11: 395–399.
35. Tarazov PG, Prozorovskij KV, Ryzhkov. Pelvic vein syndrome caused by ovarian varices. Treatment by transcatheter embolization. *Acta Radiologica* 1997; 38: 1023–1025.
36. Kim HS, Malhotra AD, Rowe PC, Le JM, Venbrux AC. Embolotherapy for pelvic congestion syndrome: long term results. *J Vasc Interv Radiol* 2006; 17: 289–297.
37. Kwon SH, OH JH, KO KR, Park HC, Huh JY. Transcatheter ovarian vein embolization using coils for the treatment of pelvic congestion syndrome. *Cardiovasc Intervent Radiol* 2007; 30: 655–661.
38. Ratnam LA, Marsh P, Holdstock JM, Harrison CS, Hussain FF, Whiteley MS, Lopez A. Pelvic vein embolization in the management of varicose veins. *Cardiovasc Intervent Radiol* 2008; 31: 1159–1164.
39. Ascitutto G, Ascitutto KC, Mumme A, Geier B. Pelvic venous incompetence: reflux patterns and treatment results. *Eur J Vasc Endovasc Surg* 2009; 38: 381–386.
40. Menard MT. Nutcracker syndrome: when should it be treated and how? *Perspect Vasc Surg Endovasc Ther* 2009; 21: 117–124.
41. Neglen P, Hollis KC, Olivier J, Raju S. Stenting of the venous outflow in chronic venous disease: long term stent related outcome, clinical and hemodynamic results. *J Vasc Surg* 2007; 46: 979–990.
42. Raju S, Owen SJ, Neglen P. The clinical impact of iliac venous stents in the management of chronic venous insufficiency. *J Vasc Surg* 2002; 35: 8–15.
43. Raju S, Yacket P Jr, Neglen P. Reinterventions for nonocclusive iliofemoral venous stent malfunctions. *J Vasc Surg* 2009; 49: 511–518.
44. Scultetus AJ, Villavicencio JL, Gillespie DL. The nutcracker syndrome: Its role in the pelvic venous disorders. *J Vasc Surg* 2001; 34: 812–819.
45. Hartung O, Grisoli D, Boufi M, Marani I, Hakam Z, Barthelemi P, Alimi YS. Endovascular stenting in the treatment of pelvic vein congestion caused by the nutcracker syndrome: lessons learned from the first five cases. *J Vasc Surg* 2005; 42: 275–280.
46. Basile A, Tsetis D, Calcara G, Figuera M, Patti MT, E GC, Granata A. Percutaneous Nitinol stent implantation in the treatment of nutcracker syndrome in young adults. *J Vasc Interv Radiol* 2007; 18: 1042–1046.
47. Neste MG, Narasimham DI, Belcher KK. Endovascular stent placement as a treatment for renal venous hypertension. *J Urol* 1997; 157: 1833–1834.
48. Kim SJ, Kim CW, Kim S. Long term follow-up after endovascular stent placement for treatment of nutcracker syndrome. *J Vasc Interv Radiol* 2005; 16: 428–431.
49. Shin JI, Lee JS, Kim MJ RE. Endovascular stent placement for the treatment of nutcracker phenomenon in three pediatric patients *J Vasc Interv Radiol* 2006; 17: 1063.
50. Chiesa R, Anzuini A, Marone EM. Endovascular stenting for the nutcracker phenomenon. *J Endovasc Ther* 2001; 8: 652–655.
51. Chung BI, Gill IS. Laparoscopic splenorenal venous bypass for nutcracker syndrome. *J Vasc Surg* 2009; 49: 1319–1323.
52. Ravindra KV, Eng M, Marvin M. Current management of sinusoidal portal hypertension. *Am Surg* 2008; 74: 4–10.
53. Elliot SP, Yeh B, Stoller MI. Radiologic appreciation of a spontaneous splenorenal shunt. *J Urol* 2004; 63: 776–777.