SONO CARD
FAST & FEEL

SCHALLKOPFTYPEN

Konvexschallkopf

Mittelfrequenz 3,75 MHz

Sektorschallkopf

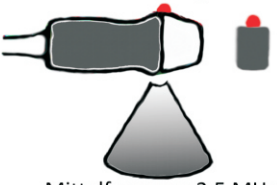

Mittelfrequenz 2,5 MHz

FAST
Focused Assessment with Sonography for Trauma

Nachweis freier Flüssigkeit bei Thorax- / Abdominaltrauma

Ziel: Reduktion der Anzahl möglicher Differentialdiagnosen

Indikation:

- Innere Blutungen
- Pneumothorax
- abdomino-thorakale Verletzung
- Hypoxie
- Schockzustand
- GCS 9
- Intubation
- Intensivstation: Ausschluss protrahierte Blutung

Blut & Flüssigkeiten stellen sich echoarm (schwarz) dar

Standardschnitte

1. Pleuraspalt rechts

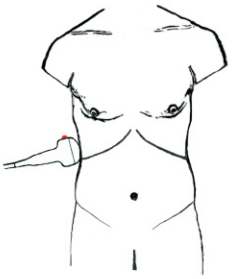

8.-10. ICR rechts in mittlerer Axillarlinie (45°)

2. Morrison-Pouch

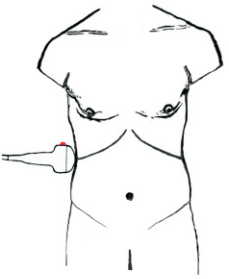

11. ICR rechts

3. Pleuraspalt links

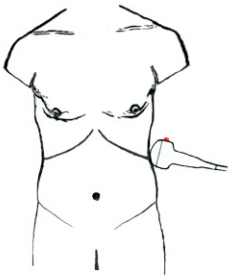

7.-9. ICR links in hinterer Axillarlinie (45°)

4. Koller-Pouch

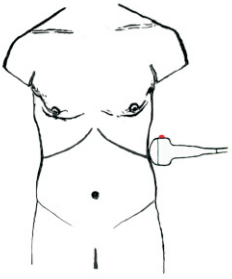

11. ICR links

5. Douglasraum

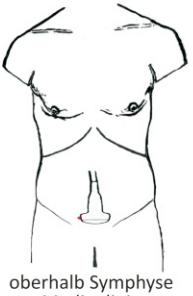

oberhalb Symphyse Medianlinie

6. Perikard

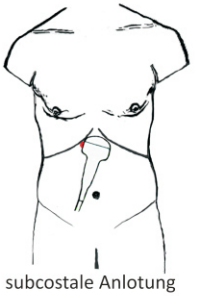

subcostale Anlotung

Kerstin Rüenauver, Florian Recker

SONO 4 STUDENTS

FACHSCHAFT MEDIZIN
KLINIK BONN

FEEL
Focused Echocardiographic Evaluation in Life support

Indikationen (HITS)

- **H**ypovolämie
  - „Kissing trabecular muscles“
  - Durchmesser der VCI < 15 mm (Normal: 20 < d < 15 mm)
  - Subcostaler 4-Kammerblick
- **I**ntoxikation
- **T**hromboembolisches Ereignis (koronar oder pulmonal)
  - Vergrößerung und Hypokinesie des RV
  - „D-Sign“ (in der kurzen parasternalen Achse)
  - Trikuspidalinsuffizienz
  - Dilatation. des Hauptstamms der Pulmonalarterie > 2 cm
  - subcostaler 4-Kammerblick / parasternale Achse
  - Septumabflachung
  - Paradoxe Septumbewegung
- **S**pannungspneumothorax
  - M-Mode
  - kein Nachweis von Pleuragleiten
  - keine Kometenschweifartefakte
  - Unterteilung Thorax in 6 Quadranten
  - Nachweis: Lungenpunkt (Beginn des Pneumothorax)
- Perikardergüsse & Perikardtamponade
  - Subcostaler 4-Kammerblick
  - „Swinging heart“

Standardschnitte

Parasternal kurze Achse

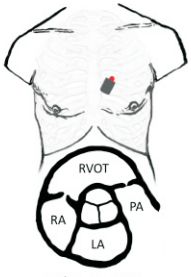

2. bis 4. ICR
links parasternal

Parasternal lange Achse

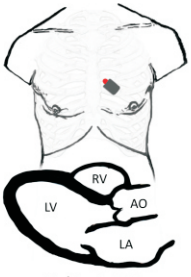

2. bis 4. ICR
links parasternal

Subcostale Anlotung

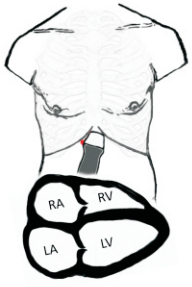

unterhalb des Processus
Xyphoideus

Apikaler Vierkammerblick

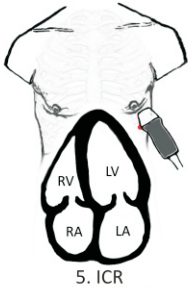

5. ICR
vordere Axillarlinie

Lunge rechts

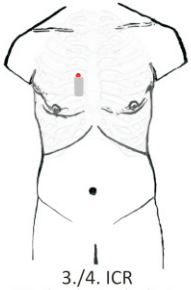

3./4. ICR
Medioclavicularlinie

Lunge links

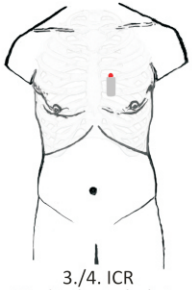

3./4. ICR
Medioclavicularlinie

alle Angaben ohne Gewähr